CT scan quiz: a 75-year-old man with abdominal pain and distension

電腦掃描猜謎：一名肚痛及腹脹的 75 歲男子

JPK Hui 許炳權, KKK Chan 陳家琪

Case

A-75-year-old male patient with history of heart disease, presented with severe abdominal pain and abdominal distension. The blood pressure was on the low side with tachycardia. The chest X-ray did not reveal any abnormal free gas under the diaphragm. The abdominal X-ray showed dilated bowels. CT abdomen was performed to look for any intraabdominal source of sepsis or obstruction (Figures 1 & 2).

Questions

1. What are the radiological abnormalities?
2. What is the clinical / radiological diagnosis?
3. How should the patient be managed?

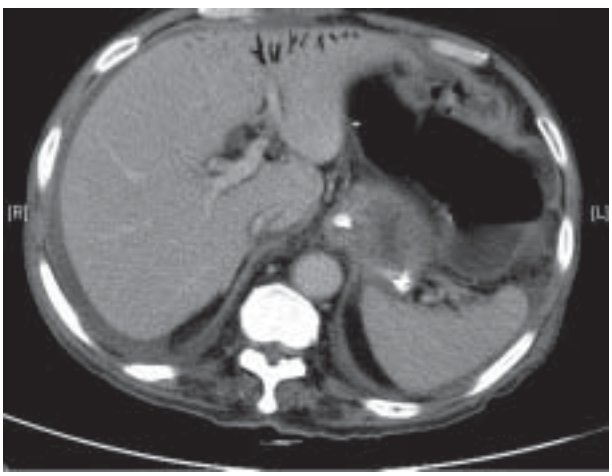

Figure 1. CT scan axial cut images of upper abdomen, including liver, spleen, and stomach.

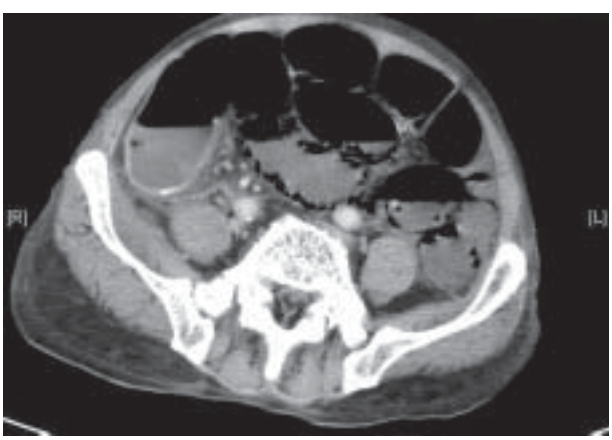

Figure 2. CT scan axial cut images of mid-abdominal region.

Correspondence to:
Hui Ping Kuen, John, MBBS, FRCR
Tuen Mun Hospital, Department of Radiology, Tsing Chung Koon Road, Tuen Mun, N.T., Hong Kong
Email: jhui@graduate.hku.hk

Chan Kar Ki, Katherine, MBBS, FRCR

Answers

1. There are diffuse bowel dilatation and bowel wall thickening. Intramural gas is noted along the small bowel wall. There is also portovenous gas within the left lobe of liver. Ascites is also noted (Figure 3a & b).
2. Ischaemic bowel.
3. Depending on the clinical condition of the patient, ischaemic bowel may be treated conservatively with supportive care like intravenous fluid replacement, antibiotics treatment and insertion of nasogastric tube. If the patient is critically ill with high fever and decompensation, surgical intervention with laparotomy and even bowel resection would be required.

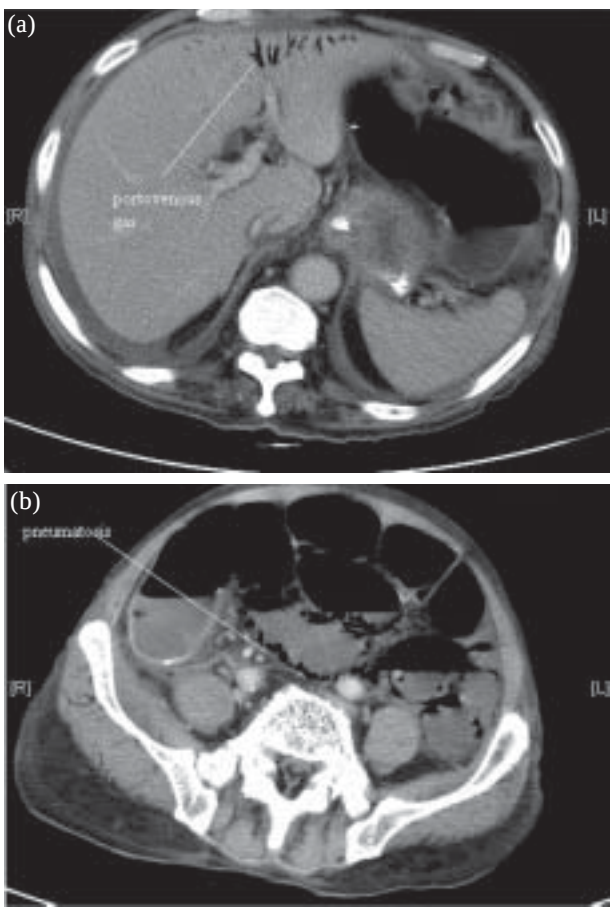

Figure 3a & b. CT abdomen showing the presence of portal venous gas and intestinal pneumatosis.

Discussion

Bowel ischaemia represents a process of insufficient blood supply of the small or large bowel. Common causes include arterial occlusion (especially those with cardiovascular disease), venous occlusion and bowel obstruction. The most common CT finding of bowel ischaemia is bowel wall thickening. Other CT findings include arterial occlusion, mesenteric or portal vein thrombosis, bowel dilatation, intramural gas (intestinal pneumatosis), mesenteric or portal venous gas.[1-3] Intramural gas is not common but is more specific of ischaemic bowel disease. It is due to the dissection of luminal gas into the bowel wall across the weakened mucosa. Mesenteric or portal venous gas is due to the propagation of intramural gas into the mesenteric venous system.

Our patient had extensive pneumatosis and also portovenous gas, representing a more severe and late stage of bowel ischaemia. Emergency operation was performed but he still succumbed afterwards.

References

1. Taourel PG, Deneuville M, Pradel JA, Regent D, Bruel JM. Acute mesenteric ischemia: diagnosis with contrast-enhanced CT. Radiology 1996;199(3):632-6.
2. Chou CK. CT manifestations of bowel ischemia. AJR Am J Roentgenol 2002;178(1):87-91.
3. Rha SE, Ha HK, Lee SH, Kim JH, Kim JK, Kim JH, et al. CT and MR imaging findings of bowel ischemia from various primary causes. Radiographics 2000;20 (1):29-42.