

Spontaneous lateral abdominal wall haematoma presenting with Grey-Turner's sign

呈現格雷·特納氏徵的自發性腹壁側血腫

CK Yuen 袁智傑, YM Chau 鄒有銘, SK Hon 韓兆基, PG Kan 簡培基, YT Wong 王友德

We describe a 93-year-old patient presenting with Grey-Turner's sign due to spontaneous lateral abdominal wall haematoma. It is a rare entity. Bedside high resolution ultrasound scan is valuable in the emergency setting to investigate a patient with Grey-Turner's sign. CT abdomen often confirms the diagnosis. These haematoma are usually benign but can have fatal complications. Management may vary from conservative treatment to intravascular embolisation or open evacuation with ligation of the bleeding vessel. (*Hong Kong j.emerg.med.* 2009;16:84-87)

我們描述一名93歲病人因自發性腹壁側血腫而呈現格雷·特納氏徵。它是一個罕有的情況。在緊急環境下，以高解像度床旁超聲波掃描調查有格雷·特納氏徵的病人是有用的。腹部電腦掃描經常會確定診斷。這些血腫通常是良性的，但可以有致命的併發症。處理可以由保守治療至血管內栓塞治療或以開放性手術去除及結紮出血的血管等差異。

Keywords: Abdominal wall, ecchymosis, haematoma, haemorrhage, ultrasonography

關鍵詞：腹壁、瘀斑、血腫、出血、超聲波造影術

Case

A 93-year-old Chinese man was brought to the emergency department in April 2008 with acute onset of right flank bruise and mild abdominal pain for three days. There was no history of recent injury. He had chronic atrial fibrillation, ischaemic heart disease, severe mitral stenosis, severe tricuspid regurgitation, hypertension and benign prostatic hyperplasia. He was taking aspirin but no anticoagulant. On examination,

he was afebrile and had mild pallor and icterus. His blood pressure was 136/64 mmHg. Grey-Turner's sign was present in the right flank (Figure 1) as well as ecchymoses in the suprapubic area. There was no palpable abdominal mass except a mild hepatomegaly. His abdomen was non-tender and bowel sounds were normal. Investigations showed haemoglobin 11.0 g/dL, white cell count $4.4 \times 10^9/L$, platelets $110 \times 10^9/L$, serum urea concentration 9.4 mmol/L, creatinine 124 $\mu\text{mol/L}$, bilirubin 42 $\mu\text{mol/L}$, alkaline phosphatase 208 IU/L, alanine aminotransferase 12 IU/L, PT (prothrombin time) 13.2 sec against a control of 10.2 sec, INR (international normalised ratio) 1.25, and APTT (activated partial thromboplastin time) 44.0 sec against a control of 32.8 sec. Chest X-ray in erect posture showed mild cardiomegaly but no free gas under the diaphragm. Bedside ultrasound of the abdomen performed by the emergency physician with an Esoate MyLab 30 machine and a 5 MHz ultrasound probe revealed a cirrhotic liver and a moderate amount of free fluid in the peritoneum. No liver mass or

Correspondence to:

Yuen Chi Kit, FHKCEM

Ruttonjee Hospital, Accident & Emergency Department,
266 Queen's Road East, Wanchai, Hong Kong

Email: yuenchikit@gmail.com

Chau Yau Ming, MRCSEd(A&E)

Hon Siu Kei, MRCSEd(A&E)

Kan Pui Gay, FHKCEM

Wong Yau Tak, FHKCEM

abdominal aortic aneurysm was detected. Ultrasound examination of the abdominal wall performed with a 12 MHz ultrasound probe revealed a mixed echogenic mass in the right lateral abdominal wall (Figure 2). A diagnosis of lateral abdominal wall haematoma was made. Urgent CT abdomen revealed a 38.1 x 64.7 x 40.3 mm right abdominal wall haematoma (Figure 3) without any sign of active bleeding. The patient was treated conservatively. The Grey-Turner's sign slowly disappeared after a week.

Discussion

Grey-Turner's sign, haemorrhagic discoloration over the flank, was first described by the British surgeon Gilbert Grey-Turner in 1919.¹ It is well known for its association with haemorrhagic pancreatitis. It is also described in a wide variety of other disorders that give rise to retroperitoneal haemorrhage such as ruptured abdominal aortic aneurysm,² ruptured renal cyst,³ ruptured hepatocellular carcinoma⁴ and cirrhosis.⁵ Grey-Turner

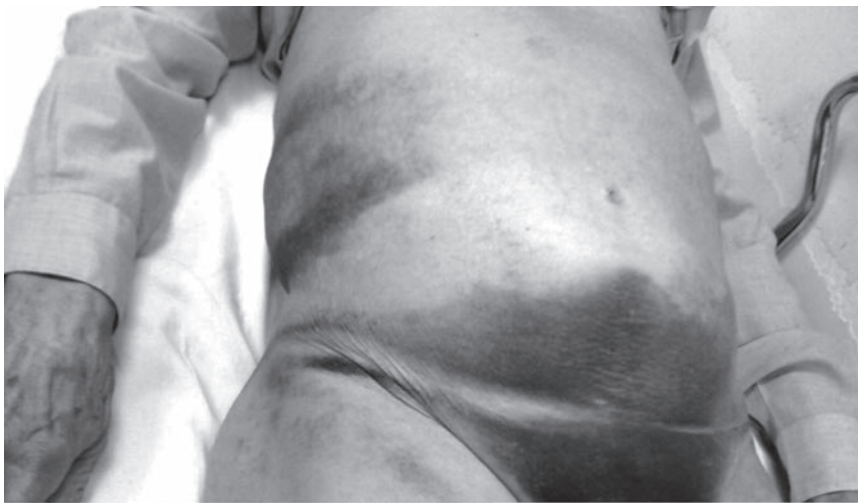

Figure 1. Grey-Turner's sign in right flank and suprapubic ecchymosis.

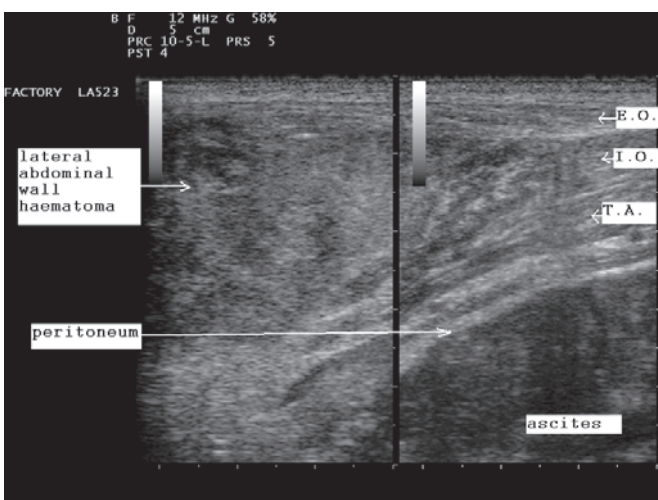


Figure 2. Transverse ultrasound scan of right abdominal wall performed by emergency physician showing a mixed echogenic mass in the lateral abdominal wall. (E.O. external oblique muscle, I.O. internal oblique muscle, T.A. transversus abdominis muscle).

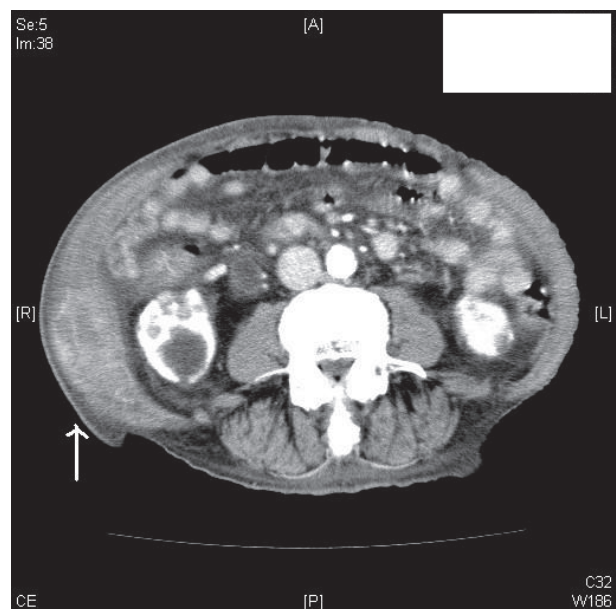

Figure 3. Transverse contrast CT scan of abdomen showing a haematoma in right lateral abdominal wall (arrow).

syndrome associated with rectus sheath haematoma has also been described.⁶ However, the clinical presentation of lateral abdominal wall haematoma with Grey-Turner's sign has rarely been reported in the literature. Spontaneous lateral abdominal wall haematoma is one located within the external oblique, internal oblique and/or transversus abdominis muscles without any preceding injury or iatrogenic procedure. It is caused by rupture of the deep circumflex iliac artery^{7,8} or tear of the internal oblique muscle.^{9,10} It is a rare disease and is usually accompanied by abdominal pain or abdominal mass. The predisposing factors are not well established but they are believed to be similar to that of rectus sheath haematoma and can be classified into three categories: (1) coagulopathy or use of anticoagulant; (2) weakening of the vascular wall by hypertension, atherosclerosis, advanced age, obesity, pregnancy, prior surgery, vasculitis, connective tissue disorders and/or inflammatory disorders; (3) over-contraction or over-stretching of abdominal wall muscle by coughing or vomiting.¹¹ Bedside ultrasonography is the first line investigation for diagnosing abdominal wall haematoma in an emergency setting. Scanning of the abdominal wall should be performed with a high frequency ultrasound probe to focus onto the relatively superficial abdominal wall layers. Ordinary trans-abdominal ultrasound with a 3 to 5 MHz ultrasound probe may miss the superficially located lesions. The abdominal wall haematoma appears as a mass of mixed echogenicity in the abdominal wall with disruption of the continuity of the abdominal wall muscle fibres. Fluid debris or fluid layer may be demonstrated. It is also important to look for other intra-abdominal pathologies.¹² CT scan can confirm the diagnosis and rule out other intra-abdominal or retroperitoneal pathologies. The features of abdominal wall haematoma are typically isodense muscle swelling or a discrete hyperdense mass with or without fluid-fluid level. Blood may track along the fascial planes. Decrease in size of the haematoma is expected in follow-up CT scans repeated in 2 to 4 weeks' time. MRI scan is valuable if the findings in CT scan are non-specific.¹² Lateral abdominal wall haematoma is usually self-limiting. If the patient is haemodynamically stable and there are no serious complications, a lateral abdominal wall haematoma can be treated conservatively with bed rest, adequate analgesia, correction of any coagulopathy and anaemia. Large haematoma may require

aspiration with or without ultrasound guidance. Urgent angiography and transcatheter embolisation of the bleeding vessel are reserved for patients with continuous bleeding. Open evacuation of haematoma and ligation of the bleeding vessels are usually the last resort when intravascular embolisation is unsuccessful in achieving haemostasis. The patient should be monitored for potential complications such as hypovolemic shock, muscle necrosis, secondary infection of the haematoma and intra-abdominal hypertension.

Conclusion

Spontaneous lateral abdominal wall haematoma can present as Grey-Turner's sign. The more common presentations are abdominal pain and abdominal mass. It is usually a benign disease but can be fatal if the bleeding is uncontrolled. Diagnosis can be reached by performing a bedside high resolution ultrasound scan of the abdominal wall in the emergency setting. CT abdomen confirms the diagnosis although MRI may be necessary in uncertain cases. Most lateral abdominal wall haematoma can be treated conservatively, but endovascular embolisation or surgery may be necessary if bleeding continues.

References

1. Grey-Turner G. Local discoloration of the abdominal wall as a sign of acute pancreatitis. *Br J Surg* 1919;7:394-5.
2. White MJ, Counselman FL. Troubleshooting acute abdominal pain. *Emergency medicine*. [cited 2008 Dec 30]. Available from: <http://www.emedmag.com/html/pre/cov/covers/011502.asp>
3. Bonani M, Franzen D, Anabitar P. Images in emergency medicine: Cullen's sign and Grey-Turner's sign. *Ann Emerg Med* 2008;51(4):448, 458.
4. Sevastianos VA, Deutsch M, Dourakis SP. Case 3. Grey-Turner's sign as the first indication of a ruptured hepatocellular carcinoma. *J Clin Oncol* 2004;22(6):1156-7.
5. Di Bisceglie AM, Richart JM. Spontaneous retroperitoneal and rectus muscle sheath hemorrhage as a potential lethal complication of cirrhosis. *Liver Int* 2006;26(10):1291-3.
6. Bene J, Lassman D, Solomon SA. Rectus sheath haematoma in elderly patients: a diagnostic challenge. *Age Ageing* 1998;27(4):512-4.

7. Shimizu T, Hanasawa K, Yoshioka T, Mori T, Kajinami T, Yokoyama K, et al. Spontaneous hematoma of the lateral abdominal wall caused by a rupture of a deep circumflex iliac artery: report of two cases. *Surg Today* 2003;33(6):475-8.
8. Katsumori T, Nakajima K. A case of spontaneous hemorrhage of the abdominal wall caused by rupture of a deep iliac circumflex artery treated by transcatheter arterial embolization. *Eur Radiol* 1998;8(4):550-2.
9. Irifune H, Kawaguchi S, Wada T, Nagoya S, Ishii S, Tamakawa M. Abdominal wall haematoma in an adolescent javelin thrower. *Injury* 2001;32(4):339-40.
10. Tai CM, Liu KL, Chen CC, Lin JT, Wang HP. Lateral abdominal wall hematoma due to tear of internal abdominal oblique muscle in a patient under warfarin therapy. *Am J Emerg Med.* 2005;23(7):911-2.
11. Kerem M, Sahin TT, Bedirli A, Azili C, Tezcaner T. Spontaneous lateral abdominal wall hematoma as a complication of status asthmaticus. *Akademik Acil Tip Dergisi.* [cited 2008 Dec 30]. Available from: <http://www.akademikaciltip.com/jvi.asp?pdire=atuder&plng=tur&volume=5&issue=8>
12. Yang WT, Lai PBS, Lee DWH, Metroweli C. Spontaneous anterolateral abdominal wall haematoma: ultrasound, CT and MR imaging. *J Hong Kong Coll Radiol* 2001;4(1):80-4.