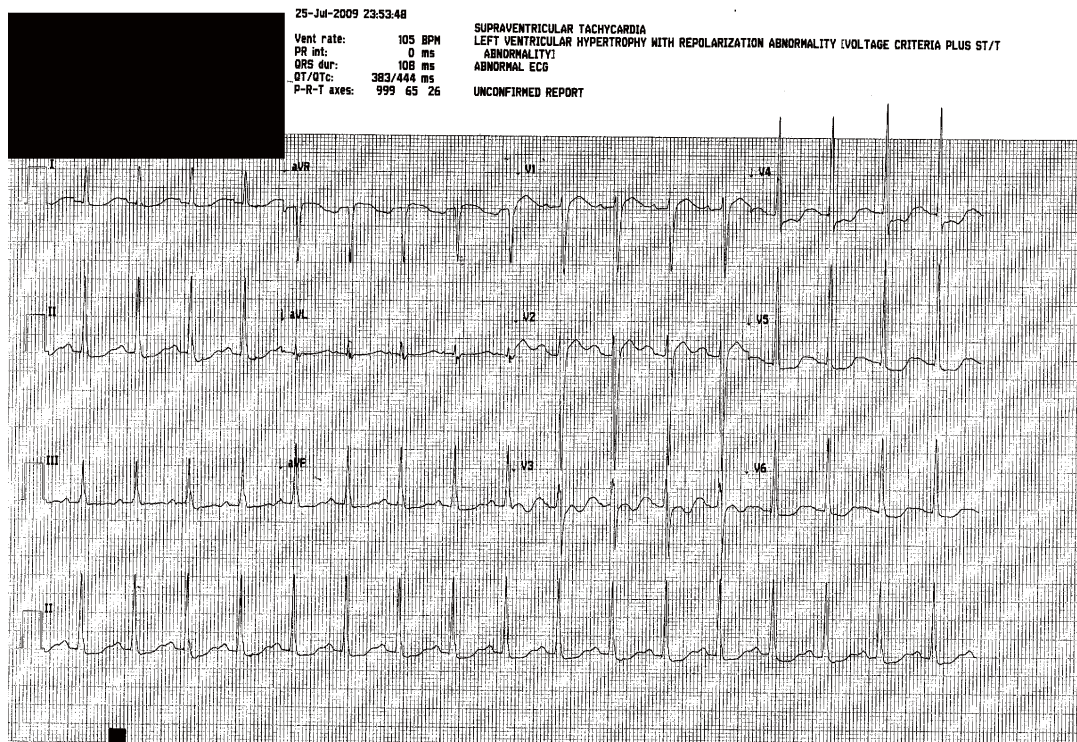


Case 1

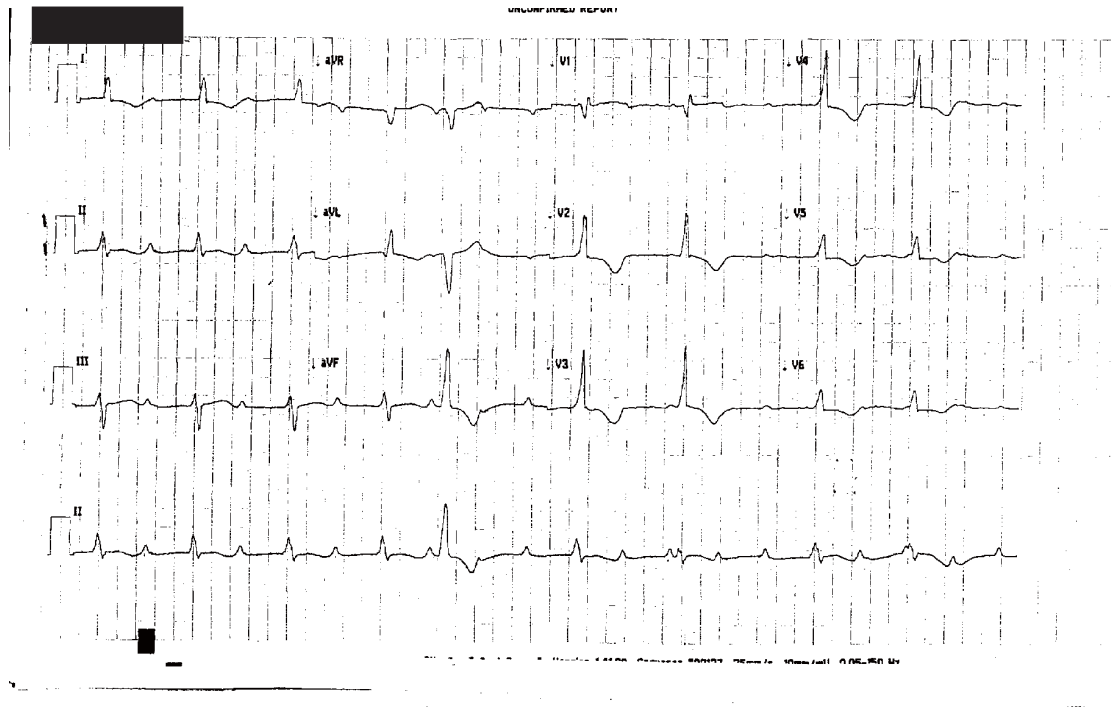
A 36 year old man enjoys good past health. Found on and off bilateral lower limb weakness in recent 3/52 after a trivial slip and fell injury. He often works outdoor and the weakness often occurs after he took a shot nap during work. Today he cannot get out of bed again. Both Lower limb proximal muscles power were 3/5. An ECG was done by nurse.



- Name 1 important ECG finding here with respect to his condition.
- Name 1 urgent investigation to be done after seeing the ECG.
- What results of the investigation do you expect?
- What is the likely condition?
- What are the precipitating factors?
- Name 1 drug that can prevent the paralytic episodes.

Case 2

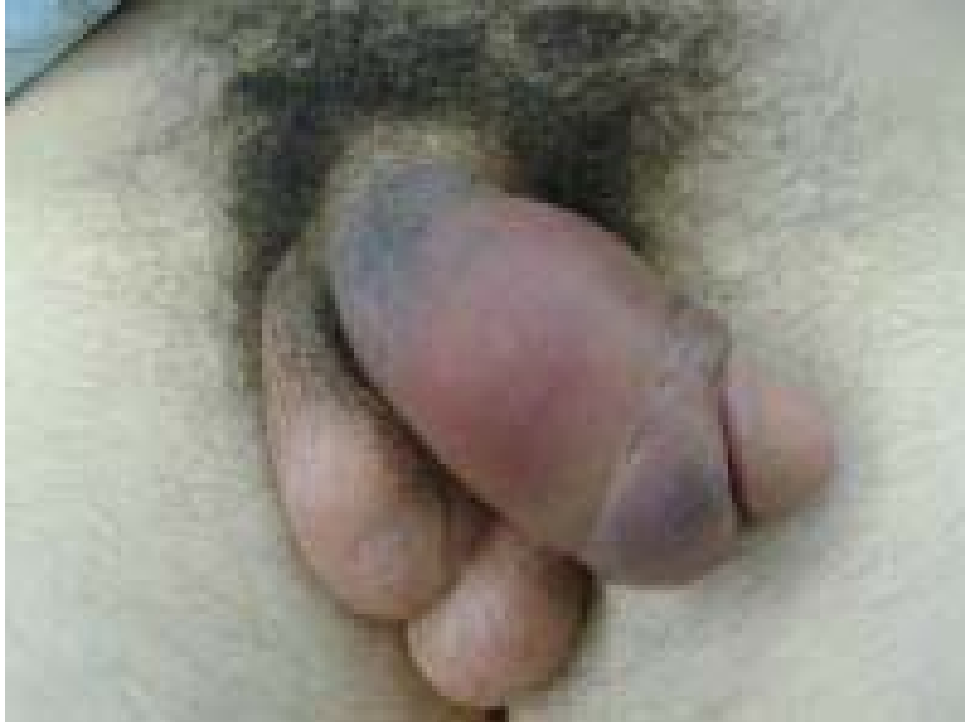A 14 years old girl is feeling dizzy and was pushed into the resuscitation room by a nurse due to a low BP of 70/40 in triage. She was alert but appeared tired looking and slightly pale. Her mother claimed that she actually had some cough and low grade fever over the past two days and then felt nausea and chest discomfort. Below is her ECG:



- describe your findings
- What is the likely cause of such ECG findings in her condition?
- Name a few culprits causing the condition in b)
- What are the initial management?
- What emergency bedside procedure would you do?

Case 3

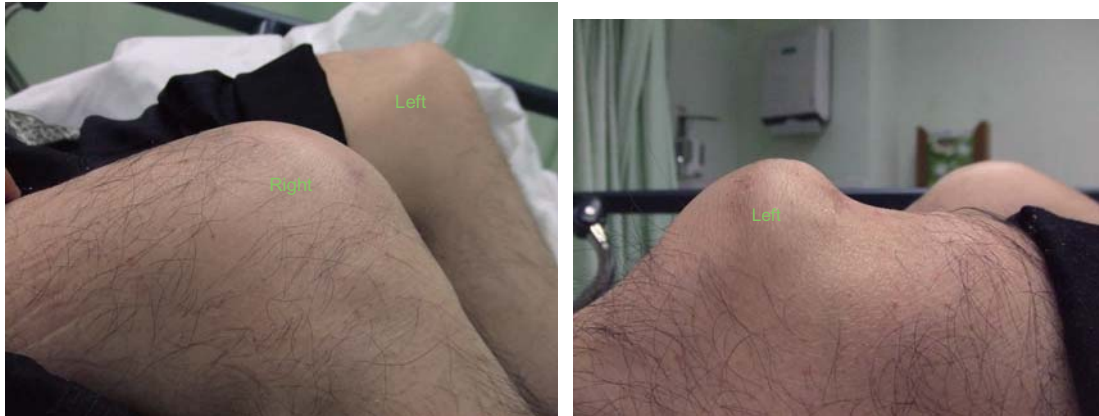A 40 years old gentleman came and complained of swollen penis for 2 hours. He volunteered that the problem occurred after he manipulated his penis himself. He was afebrile and his abdomen was soft and non tender. Below is a picture of his penis.



- a) what is this condition?
- b) Describe the clinical features here.
- c) Suggest some predisposing factors?
- d) What is the immediate management?
- e) Suggest some complications of this condition

Case 4

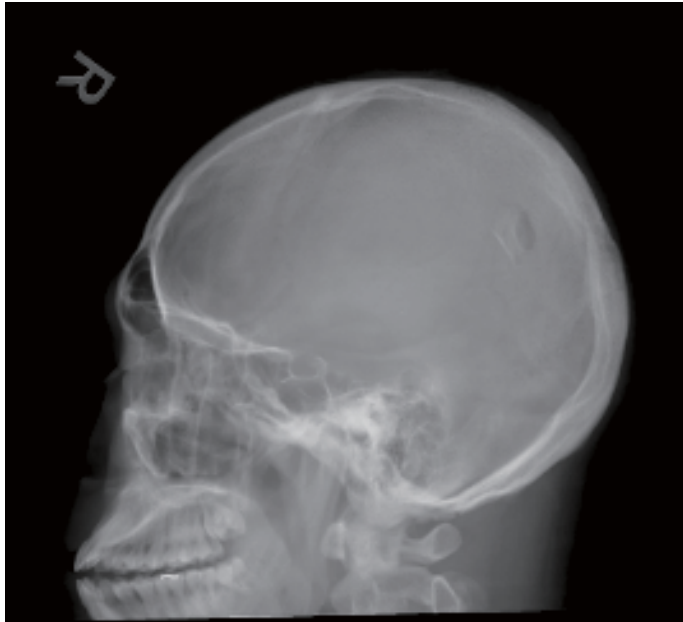A 69 years old man sprained the left knee while walking down the stairs. He claimed there was no direct contusion of the knee against the ground but he had ;a severe sprain; after his knee underwent a forced flexion and heard a ;snap;. Below is a picture of both his knees:



- describe his left knee
- what structures could be injured if the extensor mechanism is lost?
- What is the likely condition in this patient?
- Name a few factors that could predispose to the condition in c)
- Name 1 further investigation
- What would be the management then?

Case 6

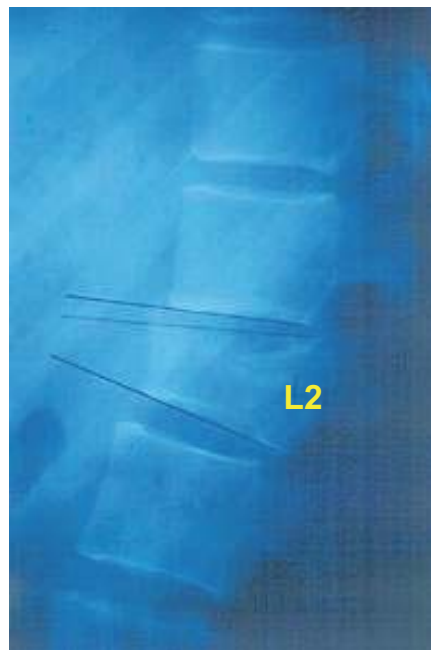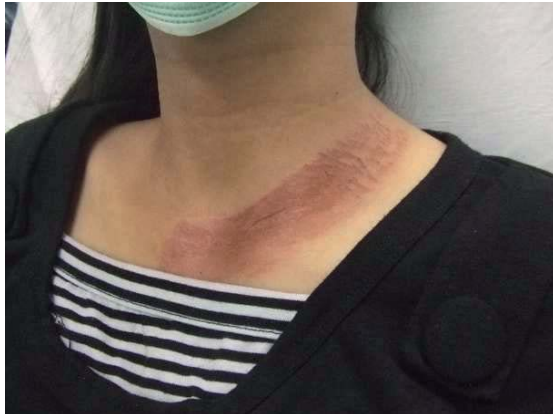A young man with dyed hair came in with a group of gangster. His body was full of alcohol smell. You could see a large, long laceration on the scalp. X-ray of the skull was done by your junior colleague:



- a) What is the finding and diagnosis?
- c) what further Ix would you do?
- d) under what situation would operation be needed?
- e) what are the risk and consequences of this condition?
- f) any drugs expected to be started during in-patient observation?

Case 7

A young lady was involved in a motor vehicle crash in highway. She was sitting in the dead seat, wearing seat-belt and the car crashed against another car in a head-on-collision. She was being sprung forward in her seat. There was no head injury or LOC. She complained of severe back pain and neck pain afterwards. Below is a clinical picture of her upper chest and an x-ray of her Lumbar spine was done with respect to her back pain:



- what is the clinical finding?
- what is being shown in the x-rays?
- What type of injury is this called?
- Which part of the body should also be examined in view of this injury as shown in the x-rays?
- is this stable or unstable?