

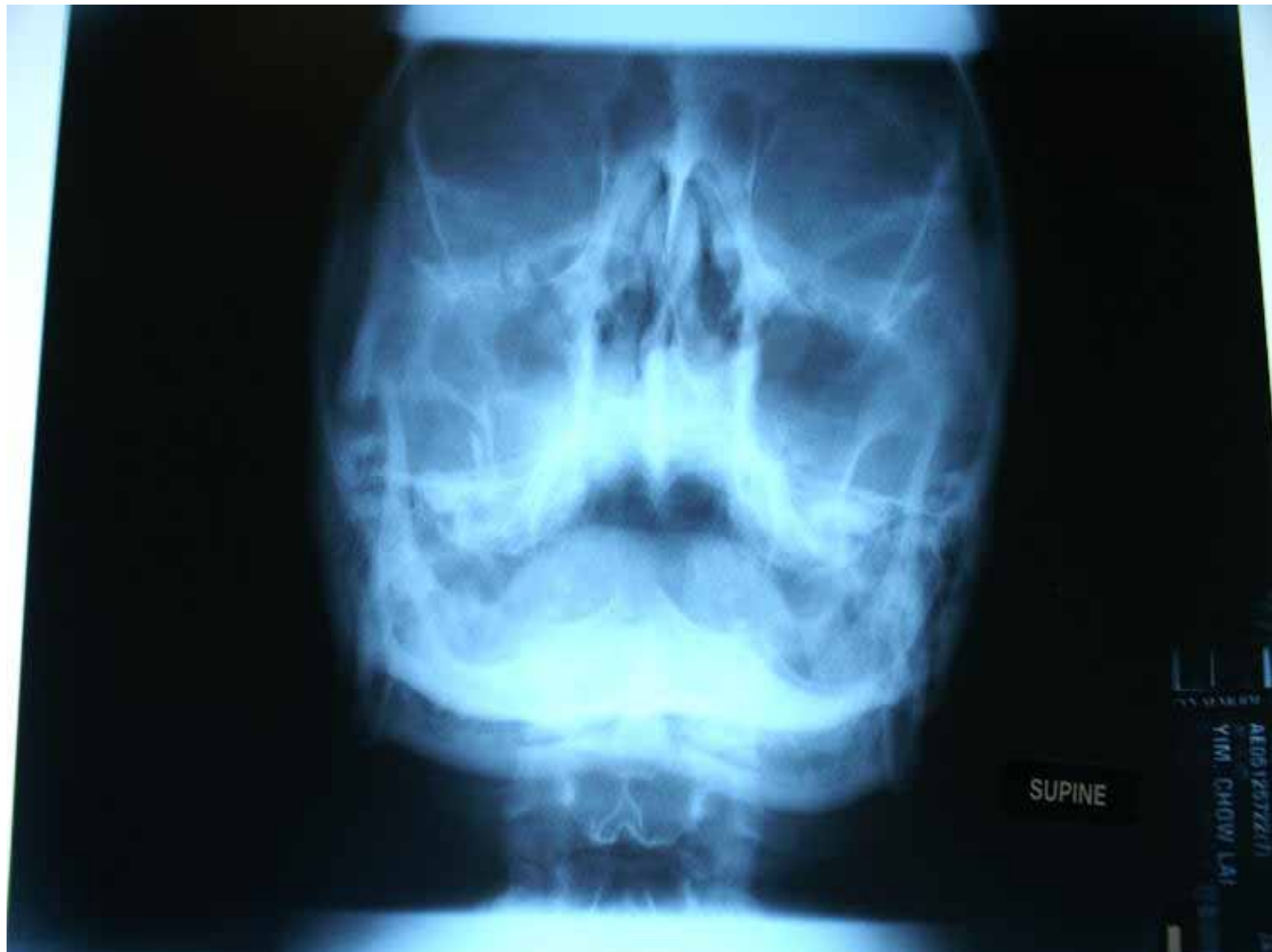OSCE

June 2006

PYNEH

Question 1

- M/65, Fall with facial injury:
 - Please give your diagnosis from the X-ray.

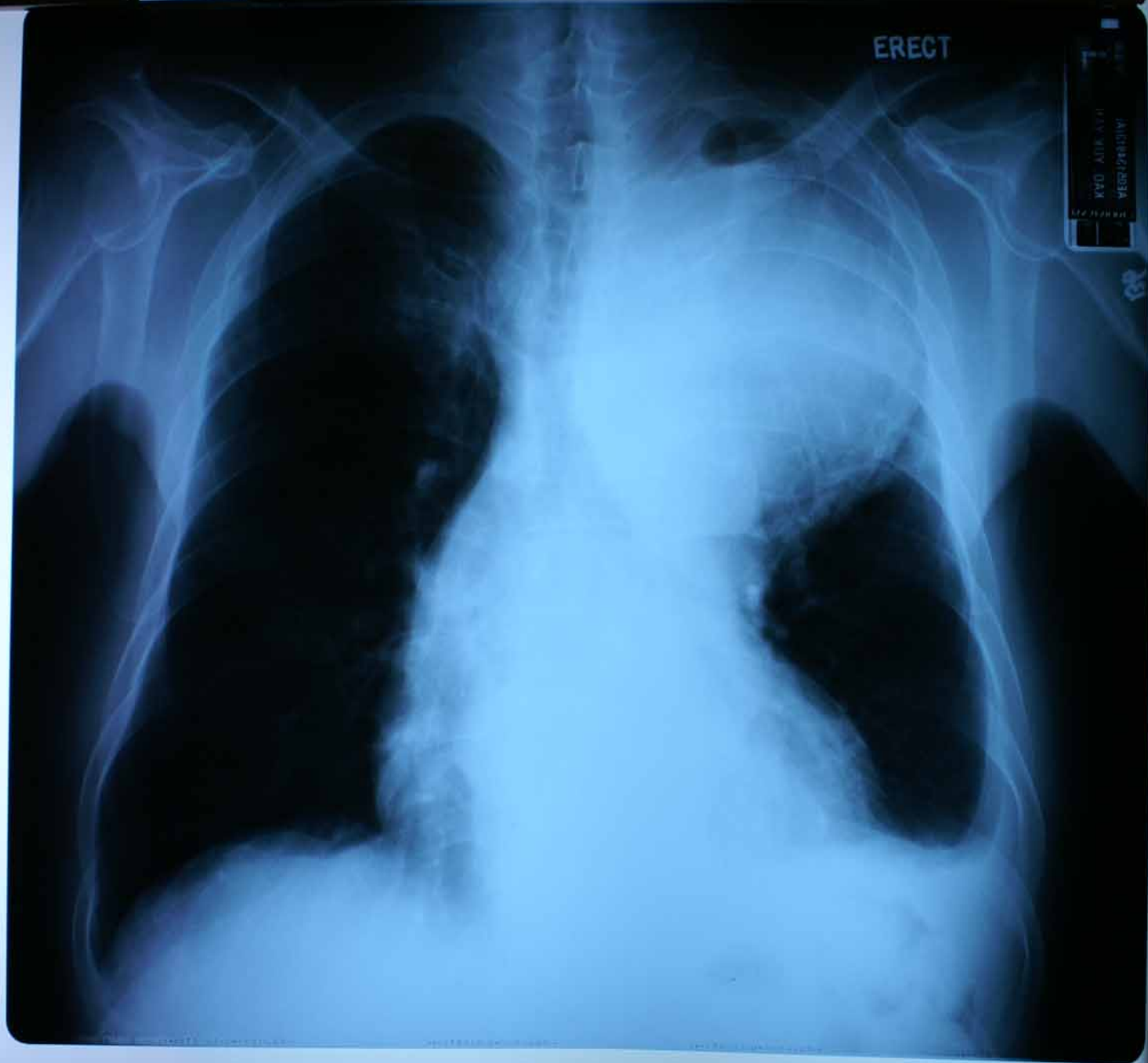


SUPINE

AUG 19 2011
YIM, CHOW, LAI

Question 2

- M/80, complaining dizziness for 1 day and the vital signs are: BP 188/110mmHg; pulse=89/min; SaO₂=95%, afebrile, GCS=15/15
 - From the very abnormal CXR, what is your diagnosis?
 - What are your immediate treatments?



ERECT

KAD ADR 100
VERZIJNDIG
12/10/08

13 W

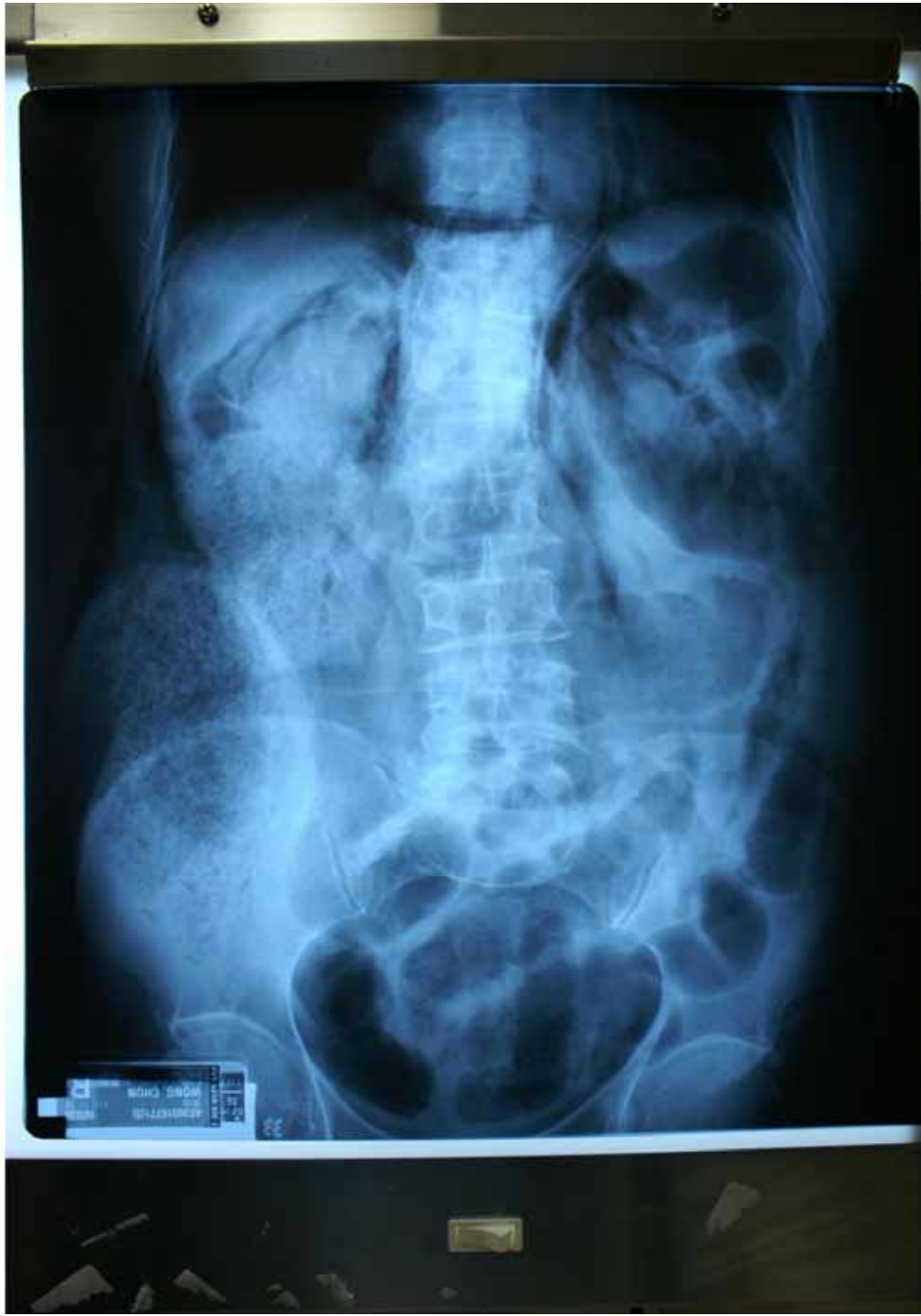- Always give - w reliable complai
- Listen & complai better th
- Don't give if there b
- Always r after give
- Never at behaving out phy
- Never sixth b

Question 3

- M/69 with past history of Ca colon with operation done before and complaining abdominal pain for 2 days.
 - Please state the abnormalities from his AXR.

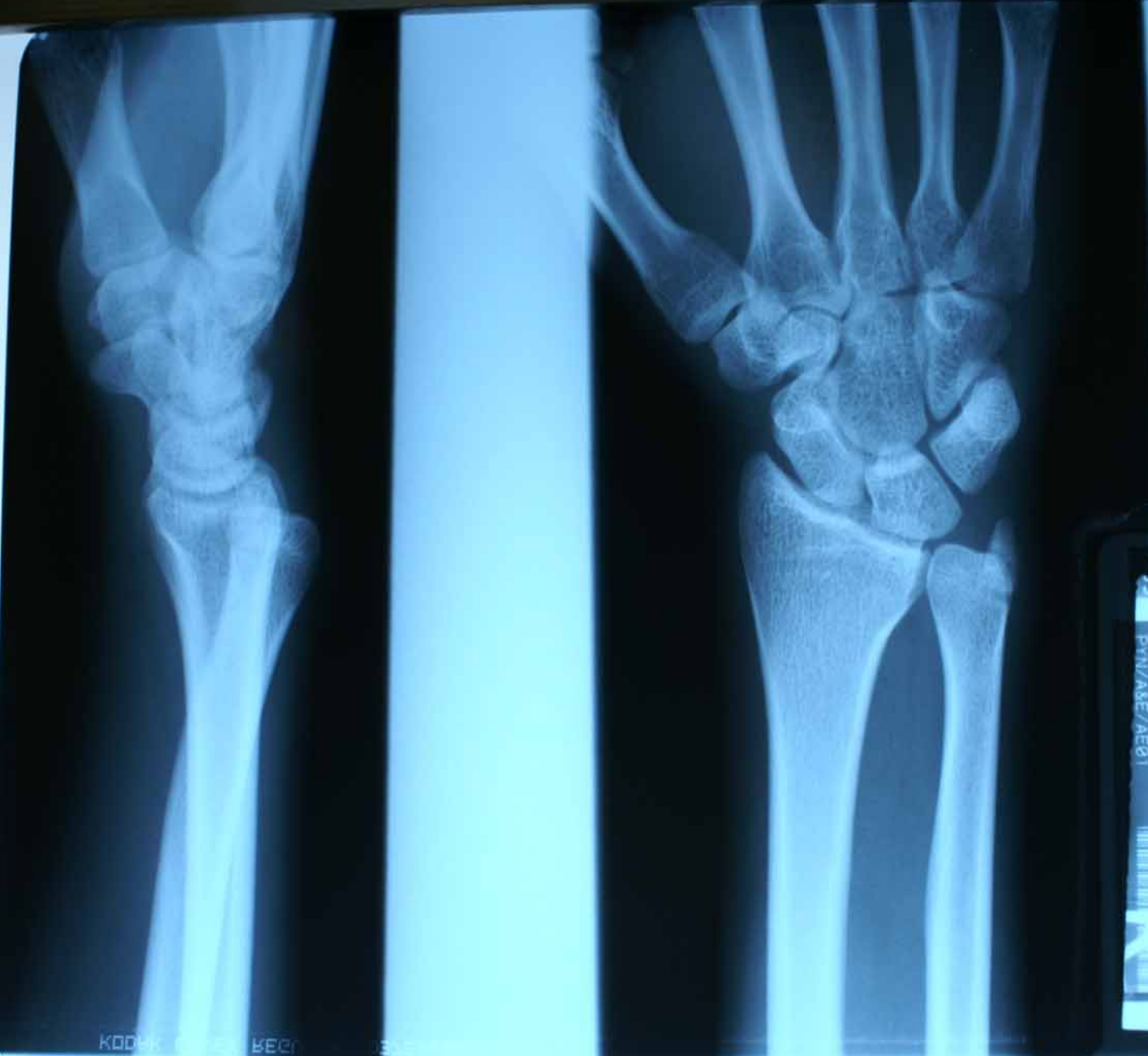Question 4

- F/90, abdominal pain for 3 days
- Admitted surgical 3 days ago with improvement on conservative treatment alone and just discharged today. She came back to A&E for increasing pain.
 - What is your finding on her AXR?



Question 5

- M/18, fall with right wrist injury
 - What are the abnormalities?
 - What is your plan of management?

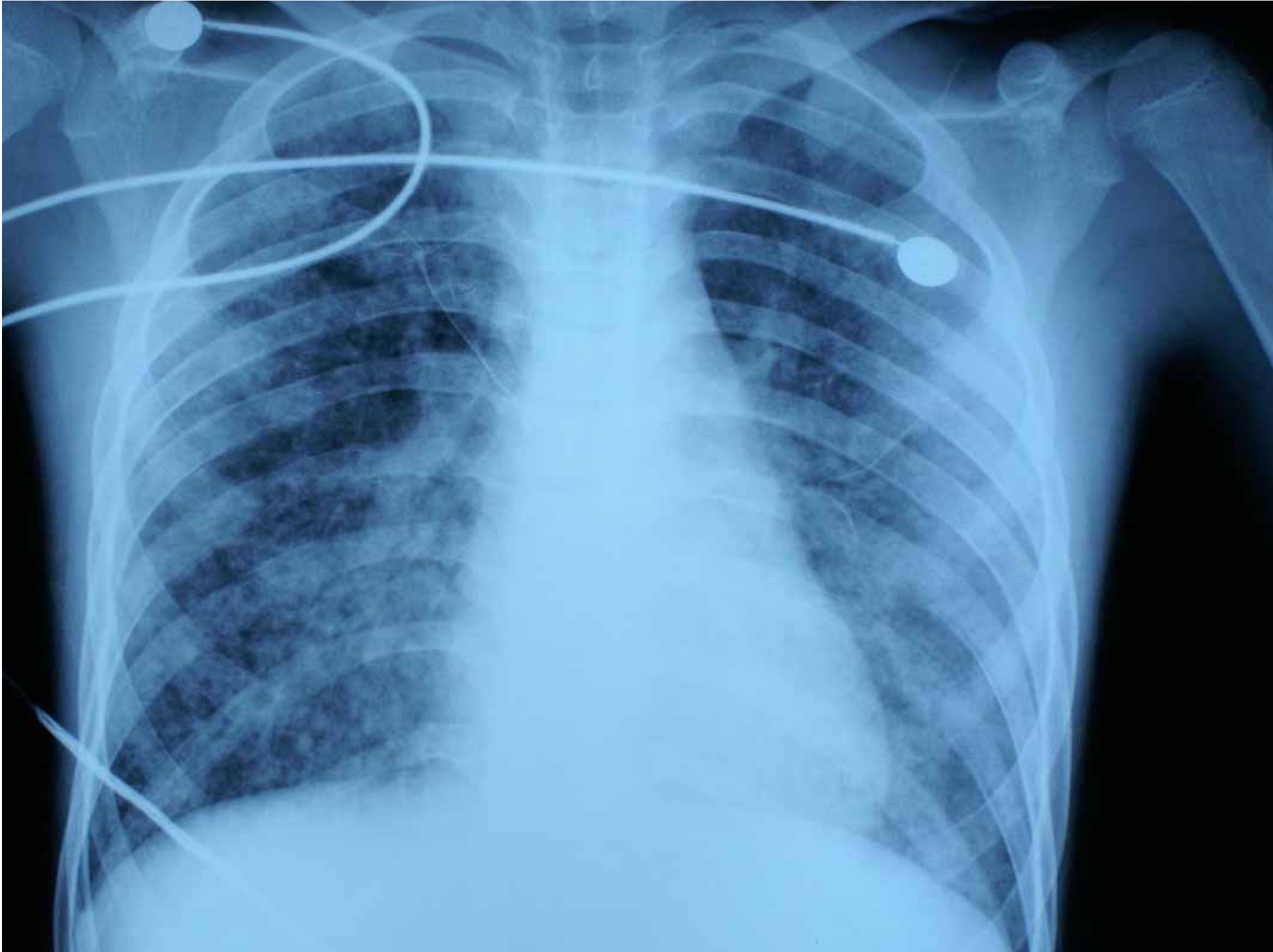


M 02:18
06
35
AE06018279(A)
彭耀軒
PANG, CHOR HIN
M/18y 2895881(A)
PYN/ABE/AE01
18/02/06
(1) 13:57
R

KODAK 0000 BECC

Question 6

- 11 yo boy, fell into sea while play skateboard and was rescued in 10 minutes time.
- He is alert all alone and SaO₂ is 94% on arrival. Other vital signs are normal.
 - What is your diagnosis after seeing his CXR?
 - What is your proposed treatment?



Thank you

Prepared by: Choi Yu Fai

PYNEH

choiyf@netvigator.com